

## Foreign body appendicitis in children: Case report

### IN BRIEF

Appendicitis caused by a foreign body is quite rare; however, ingested foreign bodies that enter into the appendix may not be able to re-enter the colon and may cause appendicitis or perforation. An accurate and prompt diagnosis is essential for minimizing morbidity. We report a case of foreign body appendicitis in an eight-year-old male child. The patient presented with pain abdomen and fever and has diagnosed with acute appendicitis. The patient was taken up for appendectomy which revealed metal balls and pebble. The patient was treated with broad-spectrum antibiotics and made an uneventful recovery.

**Key words:** Appendicitis; Foreign body; Appendectomy; Antibiotics.

### INTRODUCTION

Appendicitis is a medical emergency that requires prompt surgery to remove the appendix. Left untreated, an inflamed appendix will burst or perforate, leading to peritonitis which can be fatal [1]. The majority of ingested foreign bodies pass spontaneously, but serious complications, such as perforation and obstruction can occur [2].

#### *Case presentation*

An-eight-year old male child presented to our hospital with intermittent abdominal pain in right iliac fossa associated with mild fever since one month. The pain aggravated since two days with two episodes of vomiting. On examination, there was tenderness in the right iliac fossa and the patient was febrile. Clinically, he was diagnosed as acute appendicitis. Pre-operative blood reports were normal, ultrasonography showed inflamed appendix. The patient was taken up for open appendectomy next day. At surgery the appendix base was bulged, the tip was inflamed, and appendix was kinked (Fig 1). The content was squeezed into the lumen and appendectomy done. The content contained

**\*Jyothi S. Karegoudar, \*\*P.J. Prabhakar,  
\*\*\*Anitha M.R, \*\*\*\*Vijayanath V.**

---

\*Associate Prof. Gen Surgery, S.S.I.M.S & R. C, Davangere, Karna-taka, \*\*Prof & HOD. Gen. Surgery, S.S.I.M.S & R.C, \*\*\*Assistant Professor, Department of Anatomy, VMKV Medical College, Salem, Tamil Nadu, \*\*\*\*Associate Professor, Department of Forensic Medicine & Toxicology.

**Reprint's request: Dr. Jyothi. S. Karegoudar**, Associate Prof. Gen Surgery, S.S.I.M.S & R. C, Davangere, Karnataka.

---

Refreed Paper

Accepted on 13 July 2011

metal balls and pebble (Fig 2). There was history of ingestion of metal balls while playing, retrospectively.

## DISCUSSION

Appendicitis is common in all age groups with different aetiologies but is rarely caused by a foreign body. Balch and Silver reviewed 13, 228 appendectomies and found that a foreign body caused appendicitis is only seven of the cases, with overall incidence of 0.0005% [3]. However, Collins reported a 3% incidence of foreign-body-induced appendicitis in 71,000 cases [4].

The most common foreign bodies reported are pins, shot, bones and seeds. In addition, a multitude of miscellaneous items have caused appendicitis, including stones, shells, glass, enamel, coal, wood, nails, hair, mercury batteries, and the mercury end of a thermometer [5,6].

Very few cases of acute appendicitis have been reported to be caused by dental objects [7]. Most ingested foreign bodies pass through gastrointestinal tract without incident. However, 1-12% of these require surgical intervention either for their removal or for complications [8].

A foreign body that is heavier than the bowel content can gravitate to the dependent portion of the caecum, enter the appendix, and become lodged in its lumen [9]. Foreign bodies in the appendix can induce acute appendicitis and other complications such as perforation, which necessitate surgery [10].

The use of ultrasonography as a diagnostic tool for the early detection of appendicitis is not new. Rather, ultrasonography is commonly used as the initial imaging technique in patients suspected of having appendicitis. The diagnosis of foreign body appendicitis is difficult with plain radiography as it gives idea of presence of foreign body in the right lower quadrant but not the exact site. An aggressive treatment is indicated in most

cases of foreign-body-induced appendicitis [11].

## CONCLUSION

Acute appendicitis is a surgical emergency and delay in performing appendectomy increases the risk of perforation. Perforation of the appendix due to a foreign body can occur without classical signs and symptoms of perforation. Absence of symptoms does not preclude the presence of foreign body.

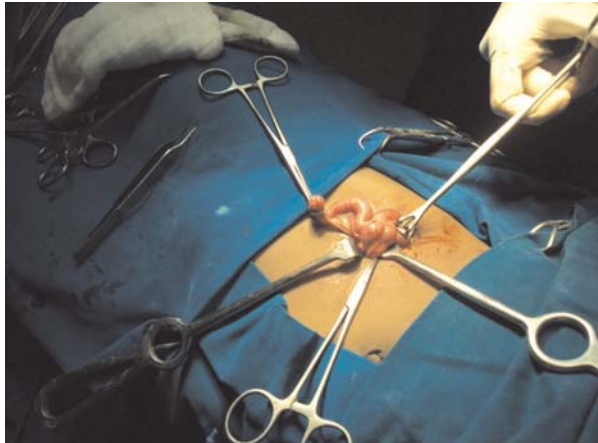
## REFERENCE

1. Hobler K. Acute and Suppurative Appendicitis" Disease duration and its implications for Quality improvement. *Permanente Medical Journal* 1998; 2(2).
2. Monte C, Uyemura, MD. Wray Rural Training Tract Family Medicine Residency Program, Wray. Colorado. *Am Fam Physician* 2005; 72(2): 287-291.
3. Balch CM, Silver D. Foreign bodies in the appendix: report of eight cases and review of the literature. *Arch Surg* 1971; 102: 14-20.
4. Collins D C. 71, 000 human appendix specimens: a final report, summarizing forty years study. *Am J Proctol* 1963; 14: 265-281.
5. Mellor T K, Mellor S G. Foreign bodies of dental origin in the appendix. *J R Army Med Corps* 1995; 141: 174-176.
6. Klingler P J, Seeling M H, De Vault K R, et al. Ingested foreign bodies within the appendix: a 100 year review of the literature. *Dig Dis* 1998; 16: 308-314.
7. Thomsen L C, Appleton S S, Engstrom H I. Appendicitis induced by an endodontic file. *Gen Dent* 1989; 37:50-51.
8. Chintamani, Singhal V, Lubhana P, Durkhere R, Bhandari S. Liver abscess secondary to a broken needle migration. A case report. *BMC Surg* 2003; 3: 8.
9. Green S M, Schmidt S P, Rothrock S G. Delayed appendicitis from an ingested foreign body. *Am J Emerg Med* 1994; 12: 53-56.

10. Klingl PJ, Smith SL, Abendstein BJ, Brenner E, Hinder RA. Management of ingested foreign bodies within the appendix: a case report with review of the literature. *Am J Gastroenterol* 1997; 92: 2295-2298.

11. Fischer CD, Mukherjee. A Appendicitis due to tongue stud ingestion: a case study and review of management plans. *SD J Med* 2004; 57: 19-22.

### Inflamed tip and kinked appendix



### Appendix specimen with foreign bodies

